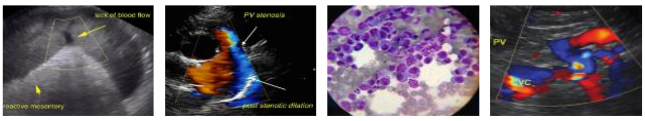

SonoPath.com
1-800-838-4268 info@sonopath.com

PATIENT
Harley Crowl

SPECIES
Canine

BREED
Labrador

SEX
MN

Age
12 years

WEIGHT
114 #

INTERPRETED BY
Remo Lobetti, BVSc, MMedVet (Med), PhD, Dipl. ECVIM

IMAGING PERFORMED BY
Sonya Myers, DVM

HOSPITAL NAME
Lake Emma Animal Hospital

REFERRING VET
Dr Lesmes

INVOICE
304108

DATE
4/11/23

PRESENTING CLINICAL SIGNS

History: Suspected splenic mass.

Physical Examination: N/A.

Urinalysis: N/A.

CBC: N/A.

Serum Biochemistry: N/A.

Radiographic Findings: N/A.

ULTRASONOGRAPHIC EXAMINATION OF THE ABDOMEN

Urinary System

Full urinary bladder with a normal thickness and appearance of the wall. Normal anechoic urine with no sediment or uroliths evident.

Normal trigone area, proximal urethra (0.5 cm), and iliac blood vessels.

Iliac lymphadenomegaly (left 1.3 x 4.3 cm, right 1 x 3 cm) with normal shape and echogenic appearance. Ureters not visualized.

Normal size (left 7 cm, right 8.1 cm) with increased echogenic appearance, some loss of cortico-medullary differentiation, and normal pelvis and capsule.

Reproductive System

Small hypoechogenic prostate (1 cm).

Adrenal Glands

Left – normal position, echogenic appearance, shape, and size (0.6/0.4 cm).

Mottled echogenic right adrenal mass (3.2 x 4.9 cm) with no obvious infiltration into the surrounding vasculature.

Spleen

Normal size (2 cm) and echogenic appearance. Smooth homogenous parenchyma, regular capsule, and normal vasculature. No inflammatory, neoplastic, infarction, or infiltrative changes evident.

Liver

Enlarged with rounded edges, hyperechogenic and nodular appearance, loss of portal markings, and regular curvilinear capsule. Nodules are hypoechogenic, parenchymal, and up to 2.4 cm in size, with some resulting in bulging of the overlying capsule. Large irregular parenchymal hyperechogenic mass (3.5 x 5.6 cm) in the left lobe.

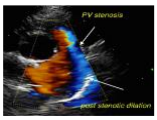
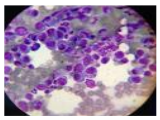
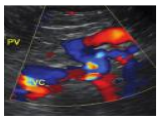

SonoPath.com
1-800-838-4268 info@sonopath.com

PATIENT
Harley Crowl

SPECIES
Canine

BREED
Labrador

SEX
MN

Age
12 years

WEIGHT
114 #

INTERPRETED BY
Remo Lobetti, BVSc, MMedVet (Med), PhD, Dipl. ECVIM

IMAGING PERFORMED BY
Sonya Myers, DVM

HOSPITAL NAME
Lake Emma Animal Hospital

REFERRING VET
Dr Lesmes

INVOICE
304108

DATE
4/11/23

Gall bladder

Full containing normal anechoic bile. Normal thickness and echogenic appearance of the wall. Normal bile duct (0.3 cm).

Gastrointestinal

Normal appearance of the stomach, duodenum, small intestine, and colon with no loss of layering, normal wall thickness (stomach 0.44 cm, duodenum 0.5 cm, jejunum 0.43 cm, colon 0.24 cm) and peristalsis, and no distension of the lumen.

Pancreas

Normal size (left 1.2 cm, right 1.4 cm) and echogenic appearance. Regular capsule. Normal echogenic appearance of the mesentery and fat surrounding the pancreas.

Free Abdomen

Normal mesenteric lymph nodes (2.7 cm).
No ascites evident.

ULTRASONOGRAPHIC FINDINGS

Primary Findings:

- Nodular hepatopathy.
- Hepatic mass.
- Right adrenal mass.
- Iliac lymphadenomegaly.

Secondary Findings:

- Age-related renal changes.

INTERPRETATION OF THE FINDINGS & FURTHER RECOMMENDATIONS

Etiologies for the hepatopathy would be nodular regeneration, chronic hepatitis, granulomatous disease, and neoplasia.

Etiologies for the hepatic mass would be extension of nodular hyperplasia, granuloma, organized hematoma or abscess, and neoplasia.

Etiologies for the right adrenal gland would be non-functional carcinoma and pheochromocytoma, with a functional carcinoma a less likely differential diagnosis.

The most likely etiology for the iliac lymph nodes would be reactive with lymphadenitis and infiltrative neoplasia, less likely differential diagnoses.

Further assessment would be 3-view thoracic radiographs, FNA cytology of the liver, hepatic mass, and adrenal mass, serial blood pressure, and adrenal function testing (ACTH stimulation/LDDS test and urine/plasma catecholamine assay). CT scan would be recommended if adrenalectomy is being considered.

Specific therapy would be dependent on an etiological diagnosis.

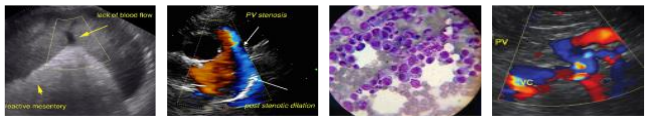

SonoPath.com
1-800-838-4268 info@sonopath.com

PATIENT

Harley Crowl

SPECIES

Canine

BREED

Labrador

SEX

MN

Age

12 years

WEIGHT

114 #

INTERPRETED BY

Remo Lobetti, BVSc, MMedVet (Med), PhD, Dipl. ECVIM

IMAGING PERFORMED BY

Sonya Myers, DVM

HOSPITAL NAME

Lake Emma Animal Hospital

REFERRING VET

Dr Lesmes

INVOICE

304108

DATE

4/11/23

IMAGES

Liver

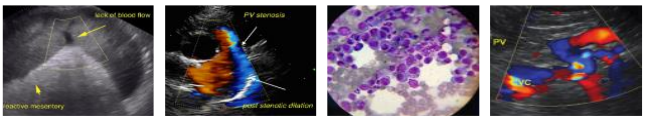

SonoPath.com
1-800-838-4268 info@sonopath.com

PATIENT

Harley Crowl

SPECIES

Canine

BREED

Labrador

SEX

MN

Age

12 years

WEIGHT

114 #

INTERPRETED BY

Remo Lobetti, BVSc, MMedVet (Med), PhD, Dipl. ECVIM

IMAGING PERFORMED BY

Sonya Myers, DVM

HOSPITAL NAME

Lake Emma Animal Hospital

REFERRING VET

Dr Lesmes

INVOICE

304108

DATE

4/11/23

Right adrenal

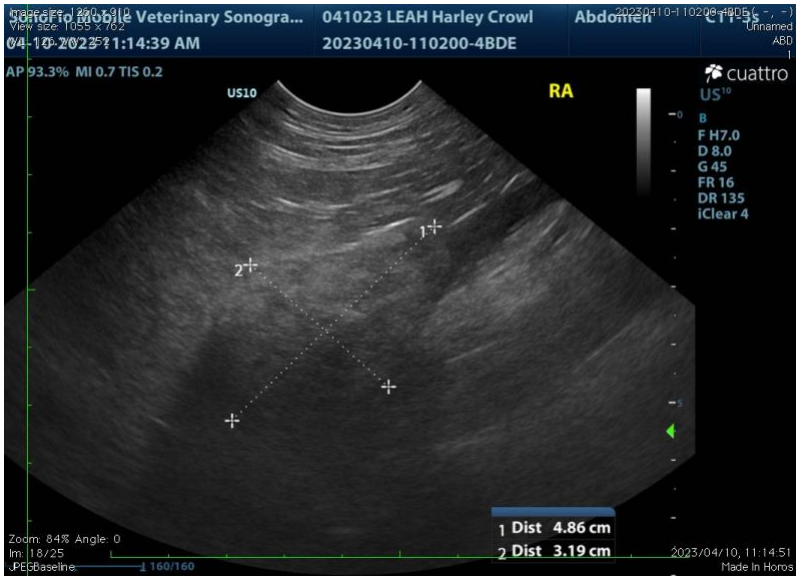

Iliac lymph node

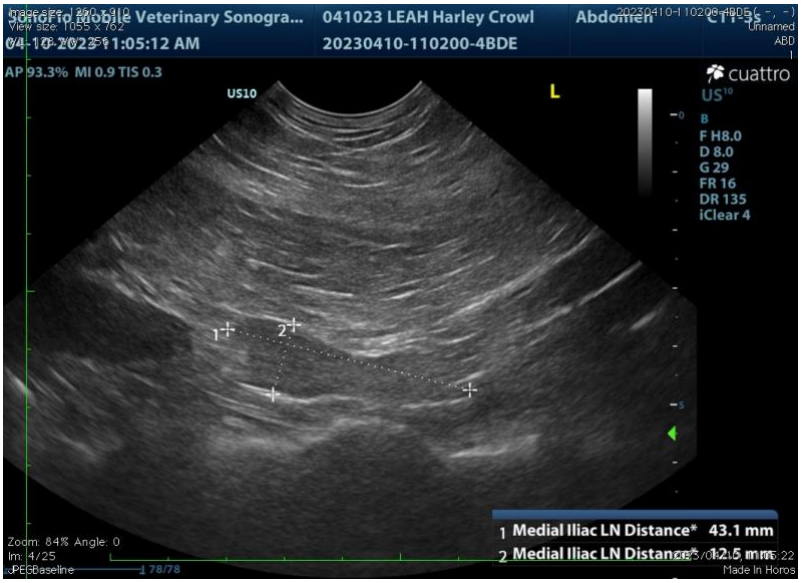

The information and recommendations provided are based on the images presented by the referring veterinarian. No evaluation can be communicated regarding pathology that was not visible in the image/video clips provided.

Thank you for this referral. If the clinical or image interpretation does not parallel your findings or if I can be of any further assistance, please contact me.

Remo Lobetti, BVSc, MMedVet (Med), PhD, Dipl. ECVIM (Internal Medicine)
rlobetti@mweb.co.za